Can lime juice cause burns? A series of paediatric phytophotodermatitis.

D. De Silva, A. Wijewardena & J. Vandervord

RNSH Burns, Plastic & Reconstructive Surgery

Introduction

Phytophotodermatitis is a term coined by Robert Klaber in 1942 to describe a skin reaction following contact with certain plants and subsequent exposure to sunlight. It mimics burn injuries, and is managed similarly. This is especially true for bullous and vesicular presentations, as seen in the cases described here.

Phytophotodermatitis specifically refers to a phototoxic skin reaction after contact with plant species containing furanocoumarins. These chemicals are found in limes, lemons and oranges (the Rutaceae family); parsley, celery and carrots (Umbilliferae family); and figs (Moraceae family). Skin reaction occurs after contact with the sensitising agent and exposure to ultraviolet A (UVA) radiation.

Cases

We present a series of 'lime burns' treated at Royal North Shore Hospital. At the close of summer 2018 a five-year-old girl and her seven-year-old brother presented with blistering and erythema on bilateral hands after picking and juicing limes in Byron Bay three days prior. The five-year-old girl experienced progression to a large fluid-filled bulla overlying the dorsum of the right hand and three metacarpophalangeal joints (Fig 1). The blisters and bulla were deroofed, debrided and dressed with Mepilex Ag. On follow-up at two weeks, the injuries had healed.

In March 2016 another case of bilateral hand erythema and blistering was seen in a seven-year-old girl two days after squeezing 200 limes (Fig 2A-B). The erythematous regions were dressed with bactigras, and the hands placed in POSI splints. At two week follow-up the wounds were healed, but areas of hyperpigmentation remained (Fig 2C-D).

All three children had a history of sunlight exposure following contact with limes.

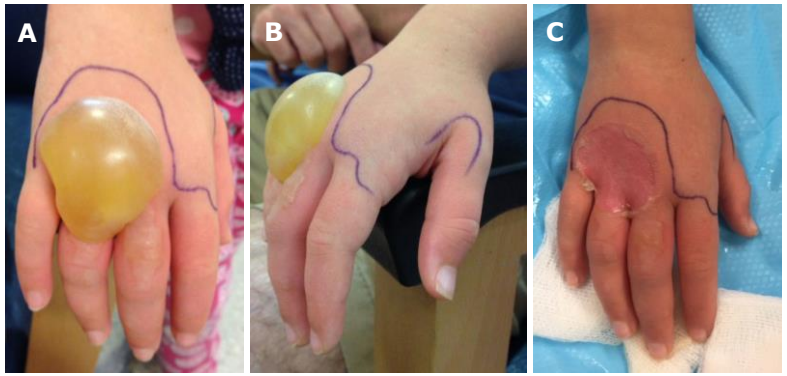

Fig 1. Right hand of five-year-old girl.
(A and B) on presentation; (C) post-debridement.

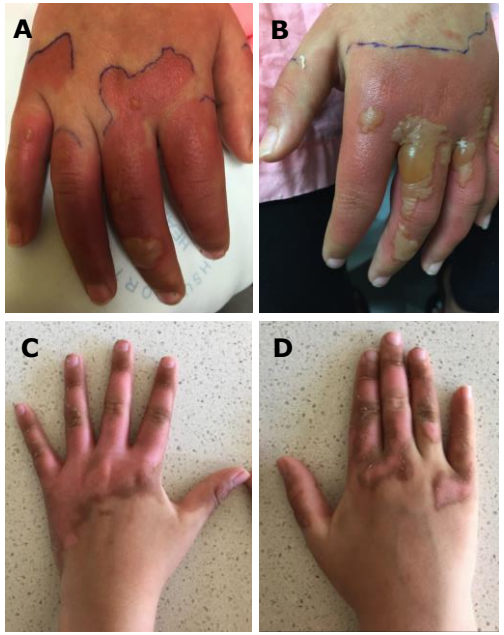

Fig 2. Seven-year-old girl.
(A) right hand on presentation;
(B) left hand on presentation;
(C) left hand at two weeks;
(D) right hand at two weeks.

Discussion

Limes contain furanocoumarins implicated in phytophotodermatitis, including psoralen, bergapten, xanthotoxin, isopimpinellin and limettin. Higher concentrations are present in the rind than the pulp. Interestingly, concentrations are highest in spring and summer. The mechanism by which the reaction occurs is twofold: activation of phototoxins by UVA radiation results in DNA cross-linking causing cell injury and inhibition of DNA synthesis. In addition, augmentation of melanocyte activity causes hyperpigmentation.

Reports in the literature describe variable severities, but with a largely consistent timeline in keeping with the cases described here: erythema appears within 24 hours, severe cases exhibit vesiculation at approximately 72 hours and exfoliation in 10-14 days. Subsequent hyperpigmentation may persist for 6 or even 12 months. Fortunately scarring is rare in children. Phytophotodermatitis may be painless, or cause burning pain. Specialised topical treatment such as dressings or steroid cream may be required. Cases involving >30% body surface area should be managed in a burns unit, and if severe enough to cause necrosis, may benefit from systemic steroid therapy.

Conclusion

Phytophotodermatitis is a self-limiting toxic skin reaction that mimics burn injuries. It causes morbidity in the acute stage due to pain and impaired hand function, and sub-acutely due to hyperpigmentation. It can be managed similar to superficial dermal burns.

References

1. Klaber RE, 1942. 'Phytophotodermatitis', Br J Dermatol, vol. 54, pp. 193–211.
2. Raam R, CeClerck B, Jhun P & Herbert M, 2016,.'Phytophotodermatitis: The Other "Lime" Disease', Ann Emerg Med, vol. 67, pp. 554-556.
3. Sarhane KA, Ibrahim A, Fagan SP, et al, 2013. 'Phytophotodermatitis', Eplasty, vol 13, ic57.
4. Wagner, AM, Wu, JJ, Hansen, RC, Nigg, HN & Beiere, RC 2002, 'Bullous phytophotodermatitis associated with high natural concentrations of furanocoumarins in limes', Am J Contact Dermat, vol. 13, no. 1, pp. 10-4.